

**MEDAVIE**

**HealthEd**

**ÉduSanté**



**SPECIFIC AREA**

**INJURY**

Advanced Care Paramedicine

Module: 05

Section: 06

- Nasal trauma
- Open wounds to the neck
- Penile trauma
- Vaginal trauma
- Ocular trauma
- Auditory injury
- Oral trauma

- Soft tissue external
- Bone / cartilage injury
- Internal vascular injury
- Posterior wall injury

- Blunt force trauma
  - Lacerations / avulsions
  - Generally minor bleeding
  - Visually unappealing
- Cared for with direct pressure / often patient directed

- Blunt force trauma
  - Underlying injuries more ominous - to be discussed during posterior wall injury
  - Result in frank bleeding which can compromise a/w patency and result in vomiting
- Cared for as with internal vascular injury and spinal immobilization

- Result of blunt trauma
  - Immobilize spine if kinematics significant
- Treated with direct pressure at nares with head tilted forward

- Blunt force trauma to face can result in fractures to cribriform plate, sphenoid sinus disruption, C-spine injury, and swelling of naso/oropharynx
  - Do not assume soft tissue / internal vascular injury only
  - Look for CSF (haloing)
- Treat with C-spine immobilization and evaluate for Total Body Involvement

- Open Wounds
  - Anterior or lateral
  - Capillary / small venous bleeding to jugular / carotid vessel disruption
- Direct pressure with dressing under opposing axilla region to prevent compression of other uninjured and vital structures
  - Can be complicated by C-spine involvement

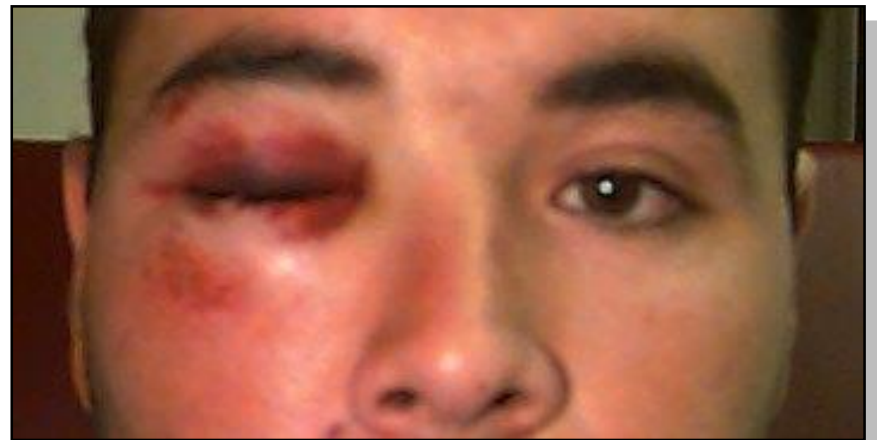
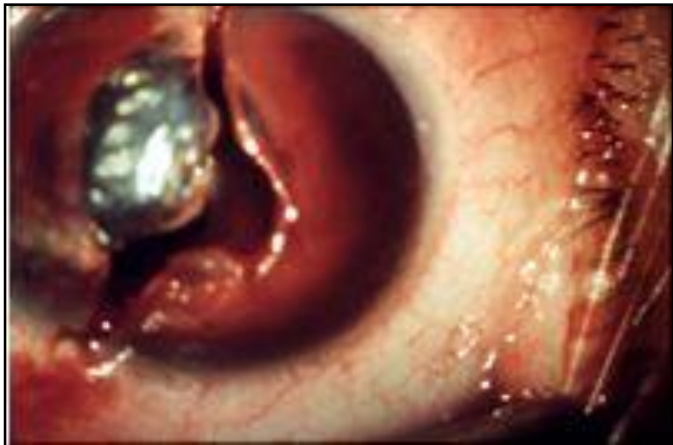
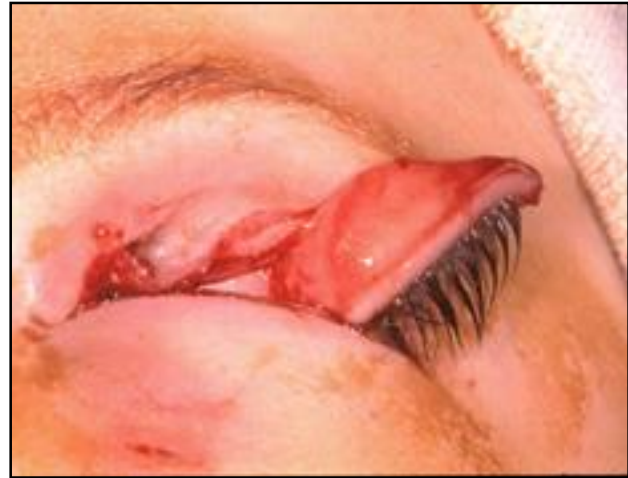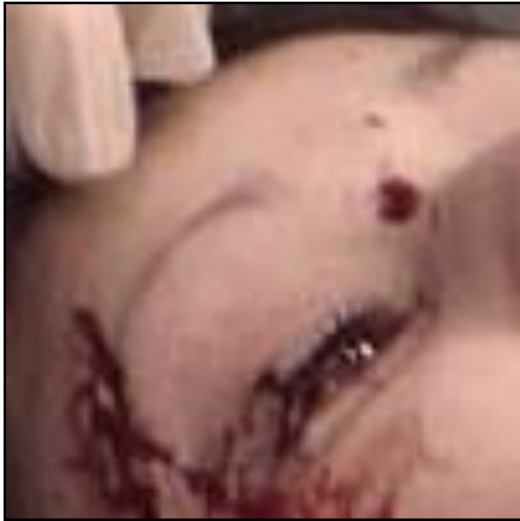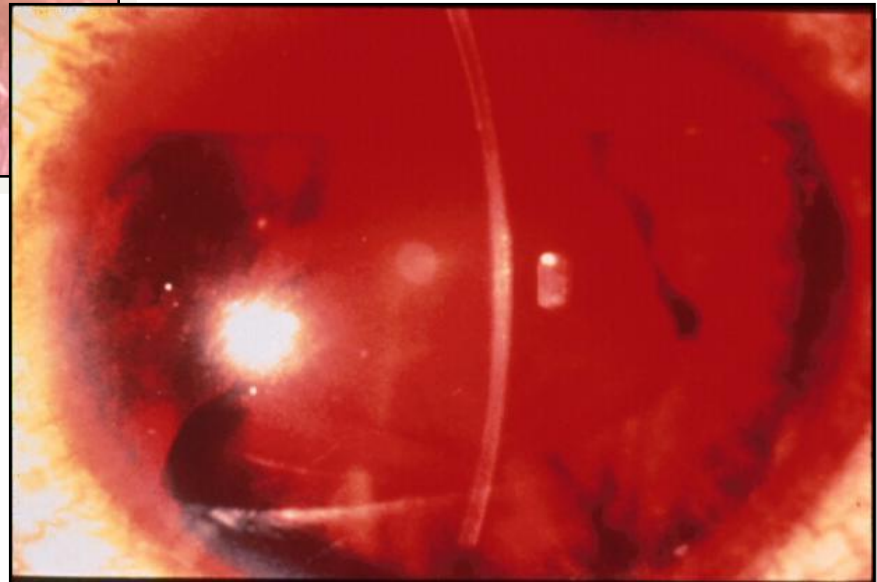
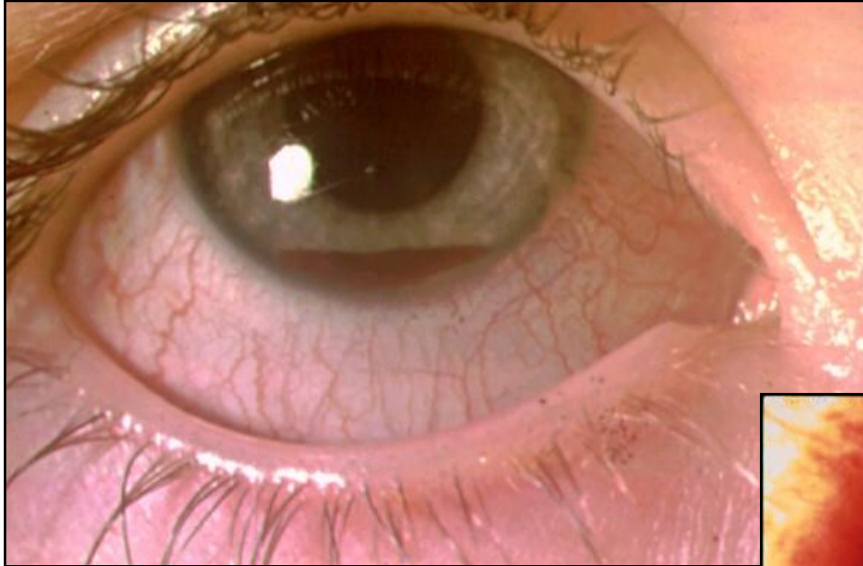
- Blunt trauma most common
  - Amputations done in anger and desperation and are treated like all others (bag of ice)
- Injuries range from mild nerve irritation to vascular involvement
  - Pelvis, spine, and great vessels may also be involved - masked due to internal location
  - Testicular rupture / hypoxia most extreme male genitalia emergencies
  - Mechanism of injury and patient distress will often identify the truly ill from the distressed

- Blunt force trauma most common
  - Penetrating trauma - sexual assault primarily
  - As with male genitalia injury, underlying injuries may be masked due to their location
  - Mechanism of injury always a deciding factor in immobilization and aggressive intervention
  - Do not pack vagina internally to stop blood flow

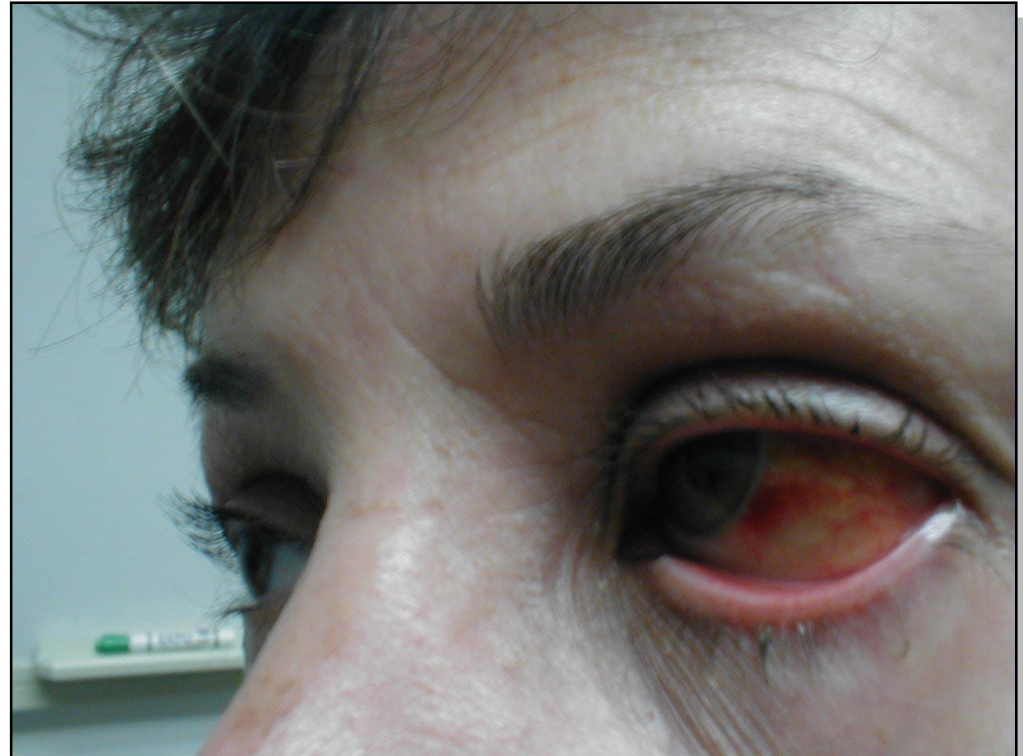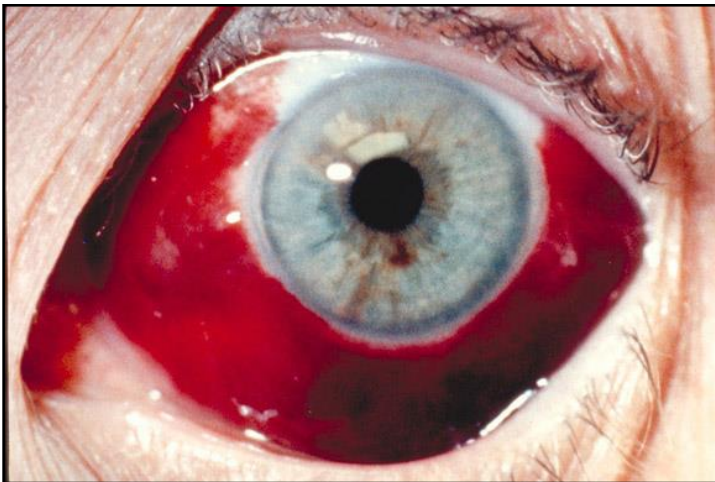
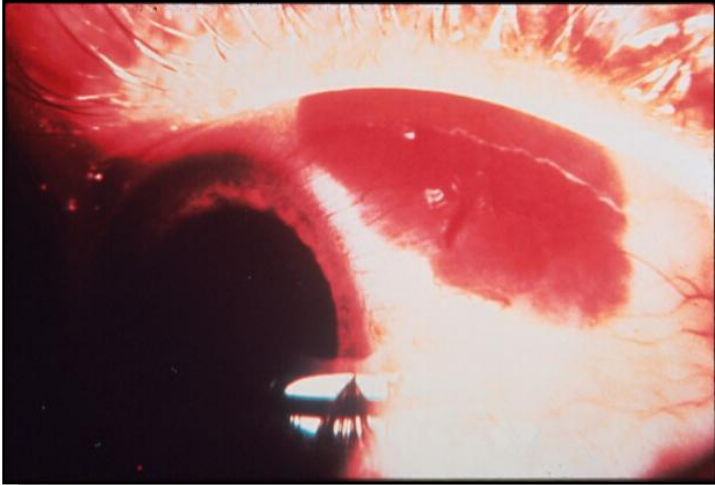
- Males can also be the victim!
  - Do not interrogate victim about incident
  - Ensure clothing / patient do not get washed
  - Package any materials in paper bag if possible
- Treat obvious injuries and look for clinical signs / symptoms of internal trauma
- If Female, female attendant (if available) may be suggested
  - Female police officer to accompany if not available

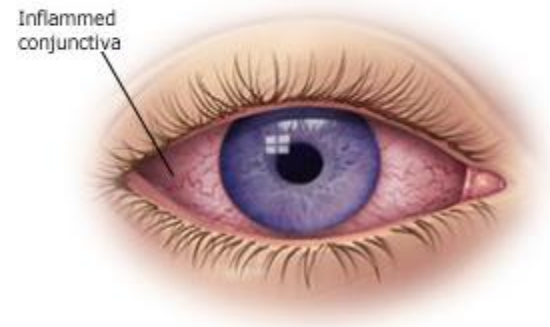
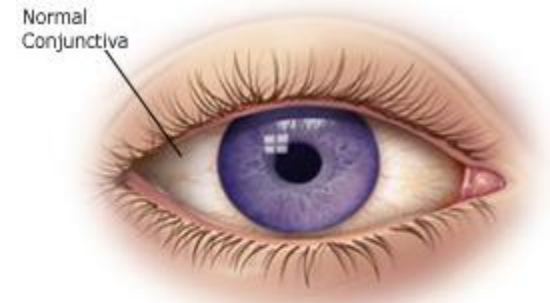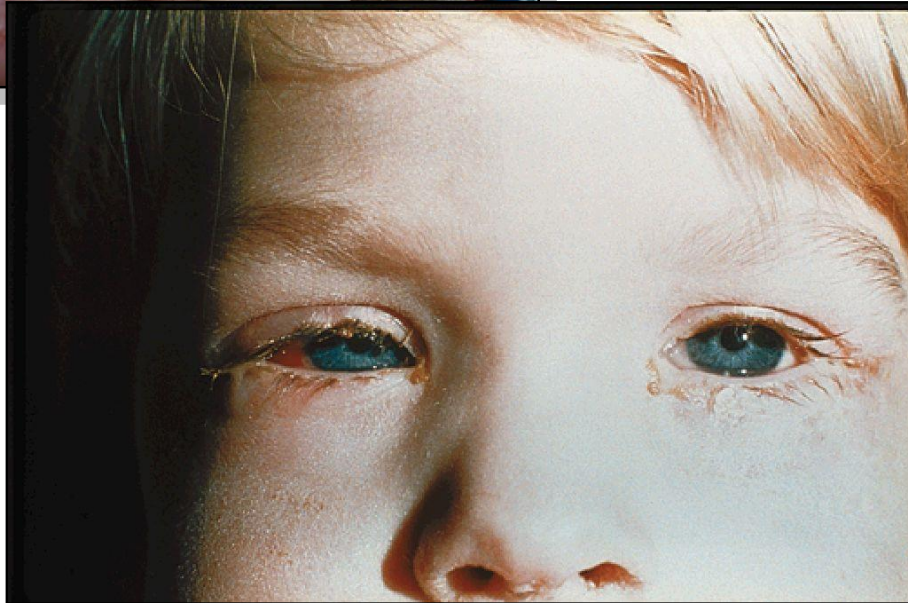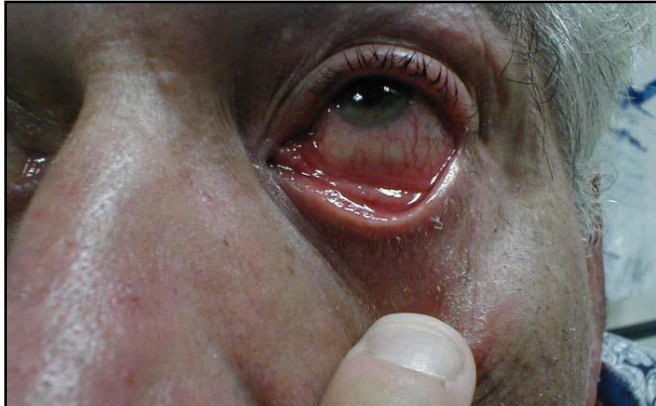- Blunt or penetrating
  - Evaluate kinematics of injury for spine involvement
  - Internal or extruded
  - Ask about visual disturbances
  - Look for pupillary reaction, and hyphema
  - If extruded cover with moist sterile dressing
  - Pad area surrounding eyeball to prevent unnecessary movement / strain on connective structures and nerves





# Subconjunctival Hemorrhage

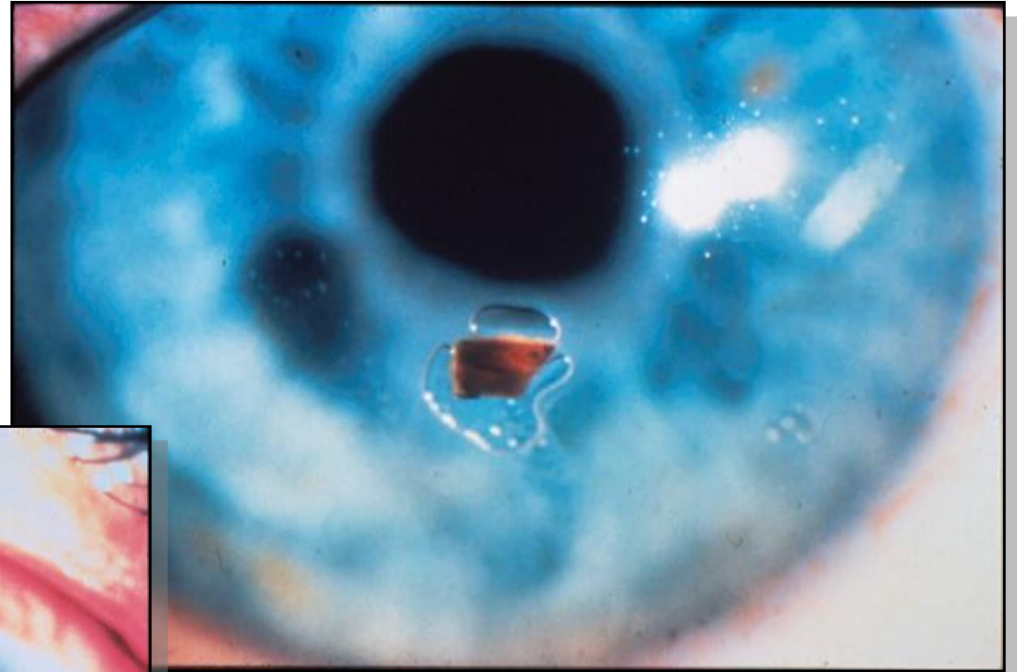
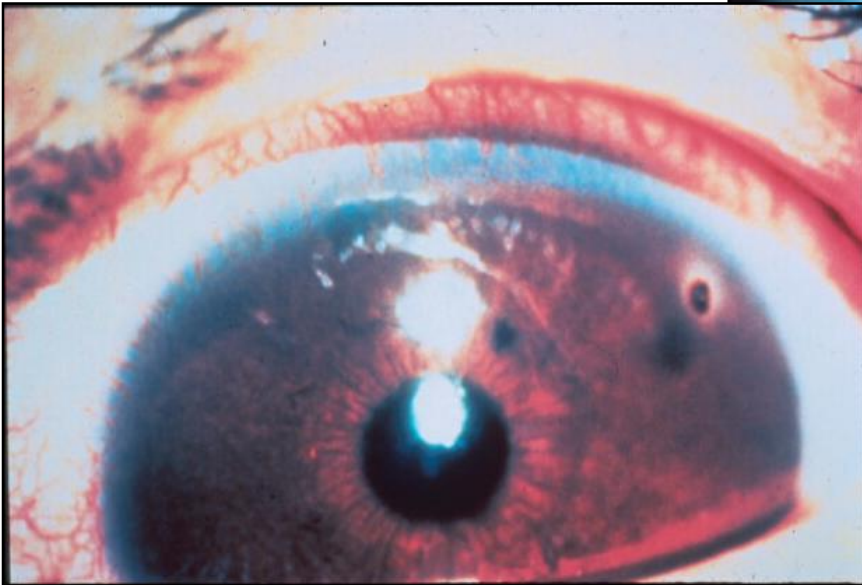




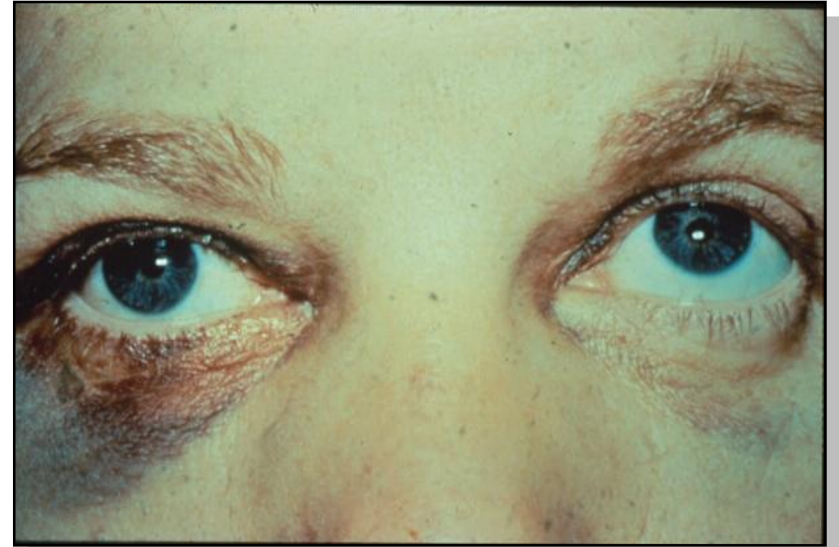
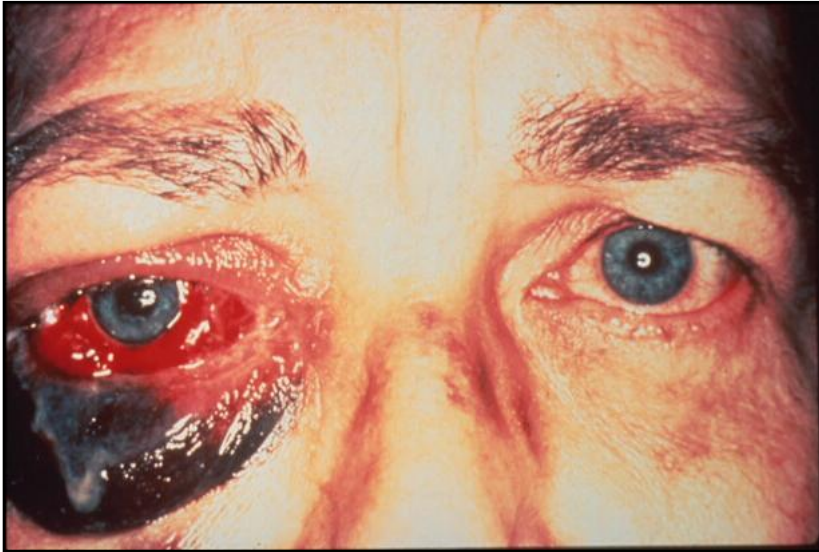
	<b>Conjunctivitis</b>	<b>Iritis</b>	<b>Acute Glaucoma</b>	<b>Keratitis</b> (foreign body abrasion)
<b>Discharge</b>	<b>MARKED</b>	None	None	Slight or none
<b>Photophobia</b>	None	<b>MARKED</b>	Slight	Slight
<b>Pain</b>	None	Slight to marked	<b>MARKED</b>	<b>MARKED</b>
<b>Visual Acuity</b>	Normal	Reduced	Reduced	Varies with site of the lesion
<b>Pupil</b>	Normal	<b>SMALLER or same</b>	<b>LARGE and FIXED</b>	Same or SMALLER

Distributed in the public interest by the Section on Ophthalmology of the Ontario Medical Association

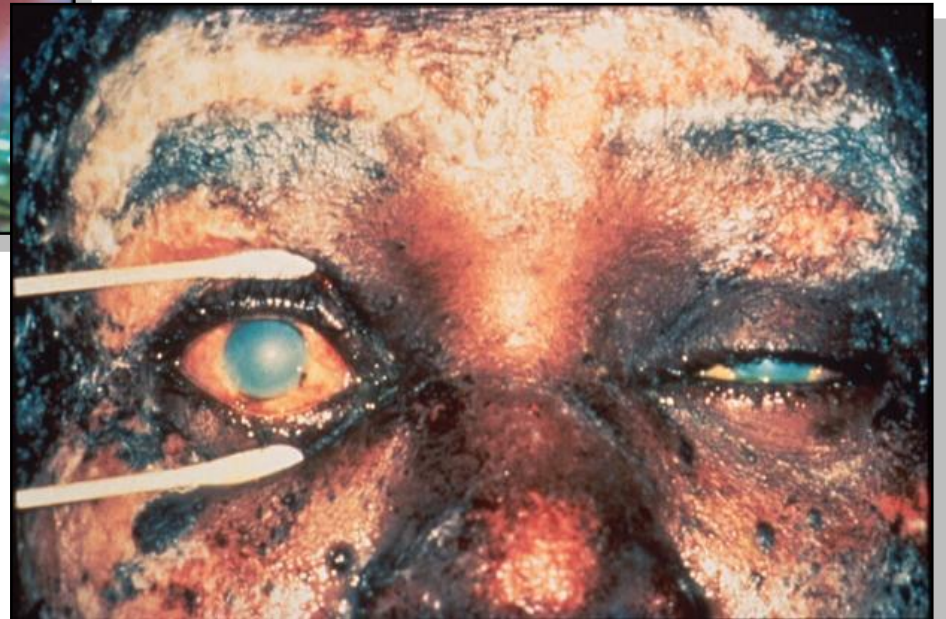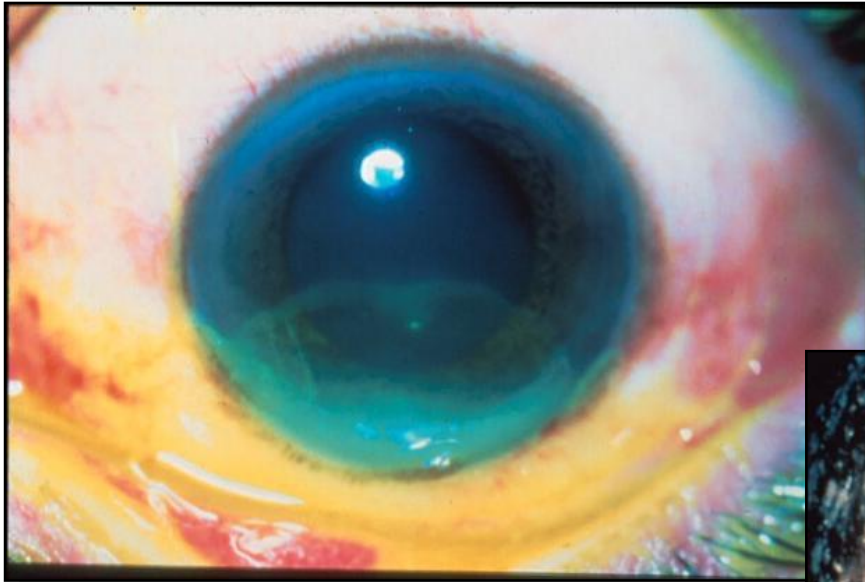


# Blowout Fractures



Note the impaired gaze?

- Initial care unchanged from PCP level
- Topical anesthetic eye drops (Lidocaine based)
  - reduces blink reflex
  - Watch for contraindications
- Flush away from nasal septum x 20 min during transport
  - Sterile water / Normal saline
- Damage may not be apparent for 24 hours



- Level of pressure the vitreous humor exerts on the globe
- Regulated by resistance to outward flow of aqueous humor
- Measured through process known as tonometry
- Increased IOP the highest indicator of glaucoma

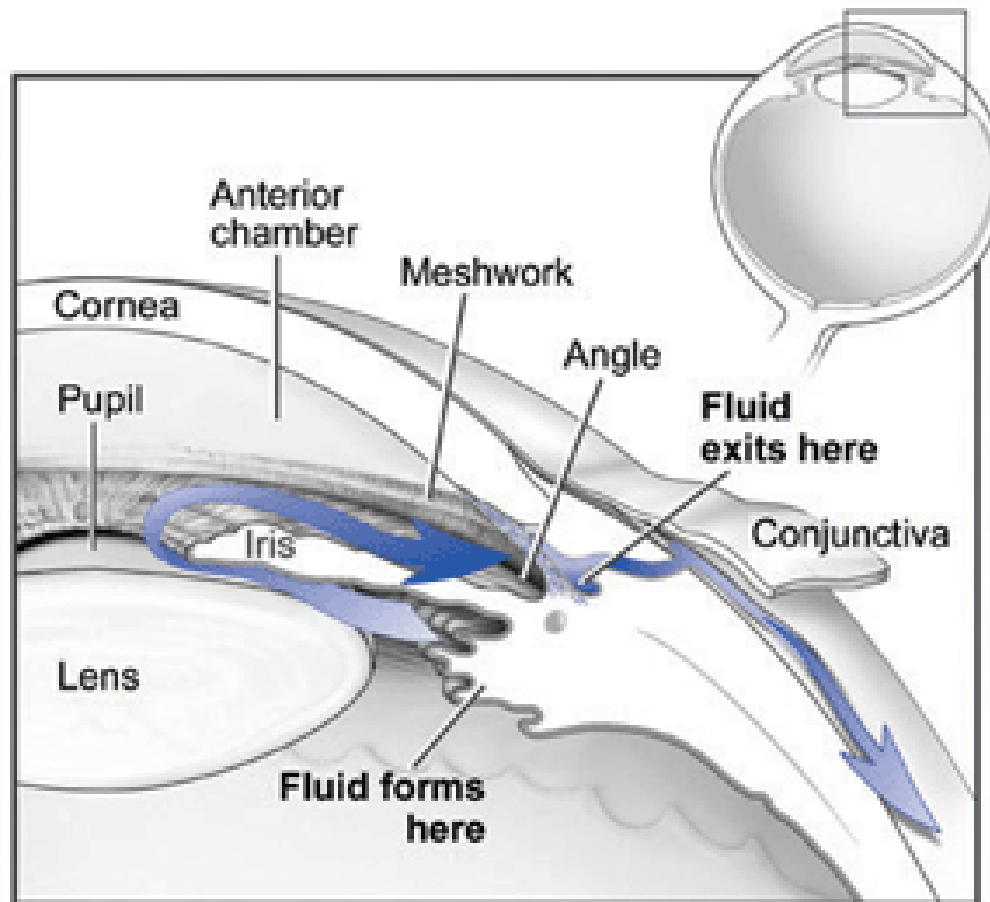
- Fluid leaves the chamber at the open angle where the cornea and iris meet
- Fluid flows through a spongy meshwork and leaves the eye
- Slow passage through the drain causes fluid and pressure buildup

- Group of diseases which damage the optic nerve
  - Causes blindness through increased pressure on optic nerve
  - Increase in pressure within the eye is not related to an increase in flow into the eye, but rather a decrease of flow out of the eye
- Types
  - Open Angle Glaucoma
  - Narrow Angle Glaucoma
  - Secondary Glaucoma
  - Congenital Glaucoma

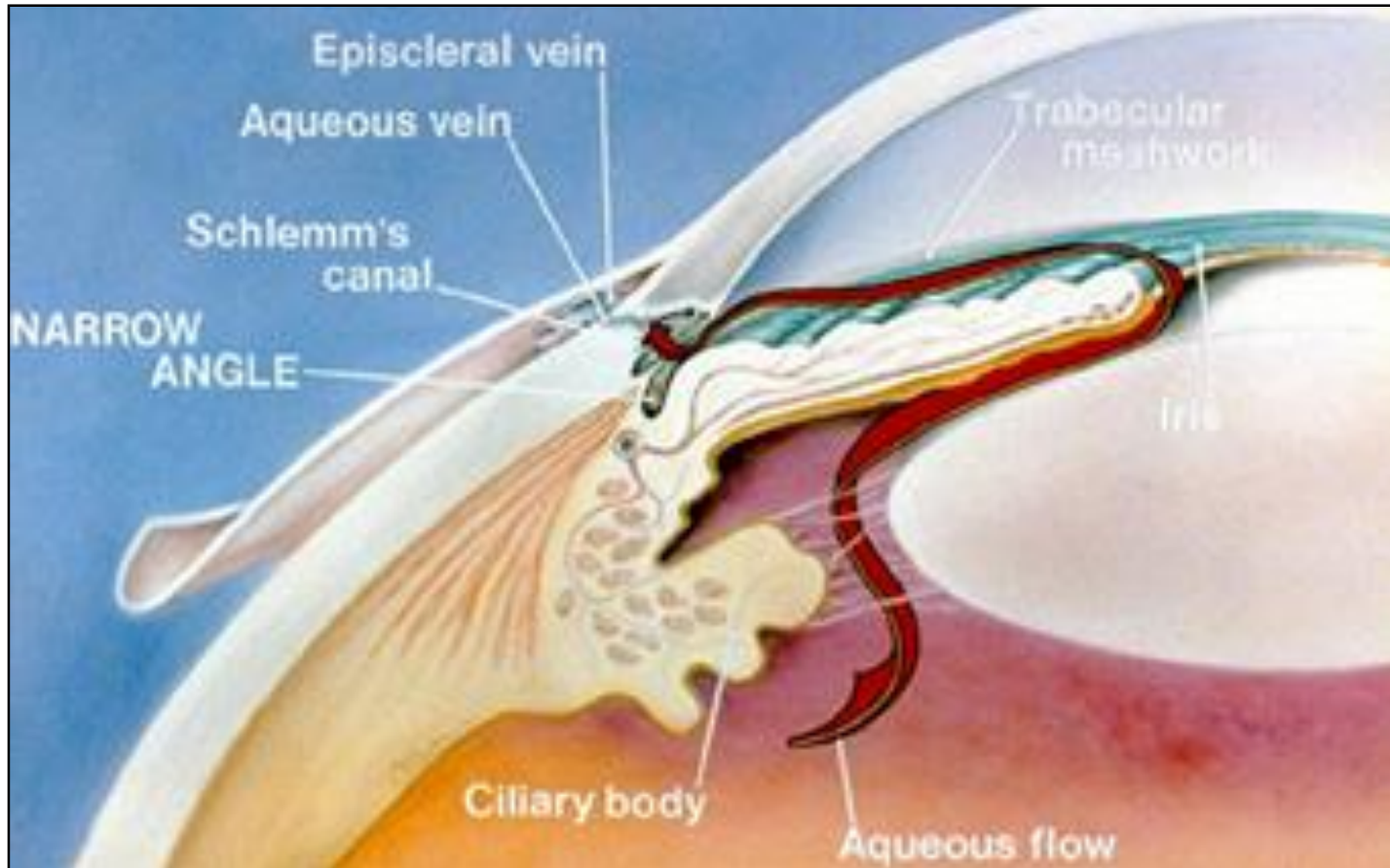


- Open Angle Glaucoma
  - visibly open drainage network
  - most prevalent kind of glaucoma which does damage slowly and silently
- Narrow Angle Glaucoma
  - a closed drainage network
  - Which can be silent or can present as an acute attack characterized by extreme eye pain, headache, and possibly vomiting
- Secondary Glaucoma
  - develops after an eye injury, disease, or even after taking some medicines
- Congenital Glaucoma
  - rare problem can put infants in danger of blindness even while they are still in the nursery.

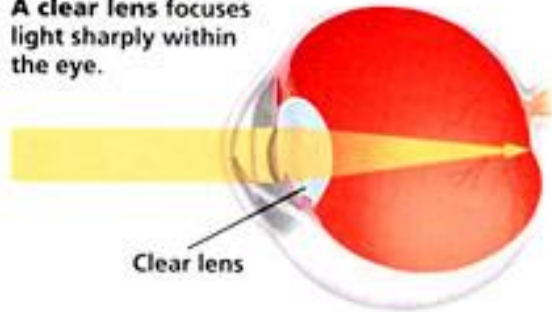
# Open Angle Glaucoma



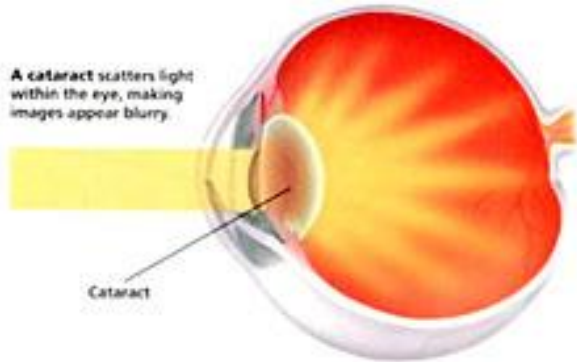
# Narrow Angle Glaucoma



A clear lens focuses light sharply within the eye.

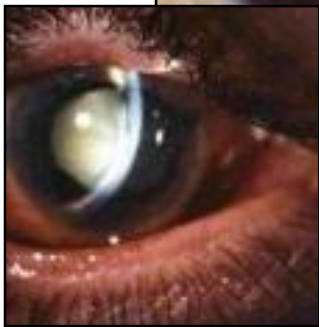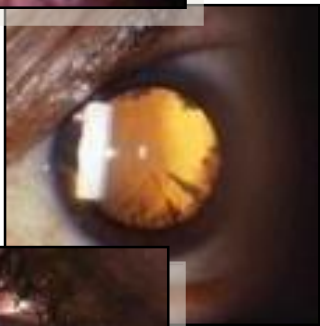
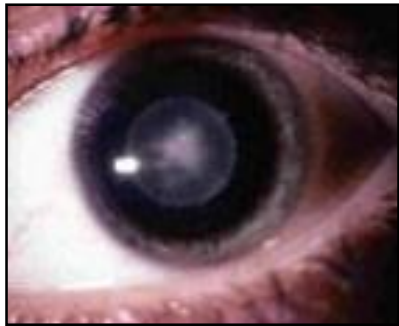


A cataract scatters light within the eye, making images appear blurry.



- Clouding of the lens of the eye caused by dead cells within the lens and the protective sac
  - Leading cause of visual loss in adults
- Causes a cloudiness to objects
- Causes:
  - Diabetes, alcoholism, trauma, and certain meds

# View through cataracts



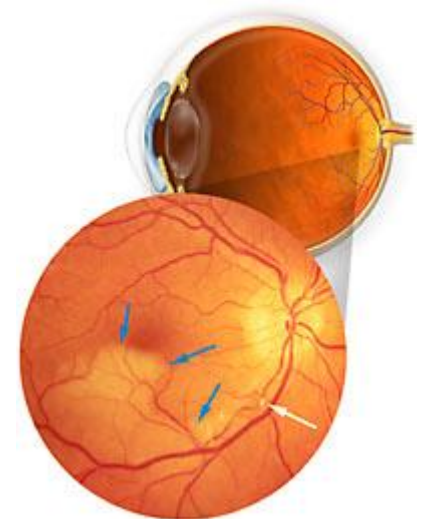
Normal vision:



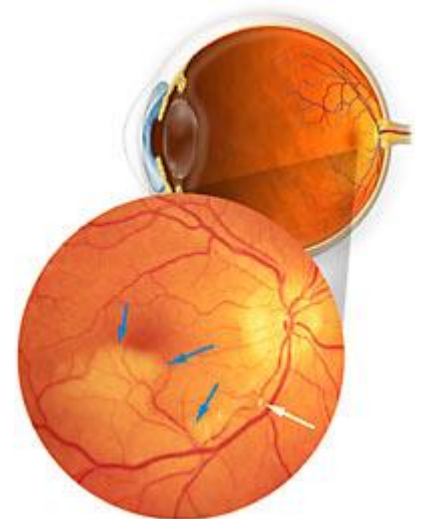
Vision through  
a cataract

# Retinal Artery Occlusion

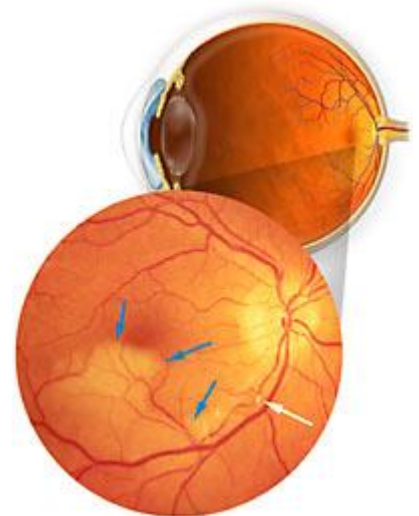
- Occurs when the central retinal artery or one of the arteries that branch off of it becomes blocked
- Typically caused by embolus
- Decreases the oxygen supply to the area of the retina nourished by the affected artery, causing permanent vision loss.
  
- Risk Factors
  - High cholesterol
  - Heart disease
  - Arteriosclerosis
  - Hypertension
  - Diabetes
  - Glaucoma



- Signs and Symptoms
  - Transient loss of vision prior to the artery occlusion (in some cases)
  - Central artery occlusion
    - Sudden, painless and complete loss of vision in one eye
  - Branch artery occlusion
    - Sudden, painless, partial loss of vision in one eye



- No treatment that can consistently restore vision
- However, if it is caught within the first hour and treatment is initiated immediately, recovery is possible in rare cases





- Retinal Tears
  - Commonly occur when there is traction on the retina by the vitreous gel inside the eye
    - In a child's eye, the vitreous has an egg-white consistency and is firmly attached to certain areas of the retina.
    - Over time, the vitreous gradually becomes thinner, more liquid and separates from the retina. This is known as a posterior vitreous detachment (PVD)
    - PVDs are typically harmless and cause floaters in the eye
      - In some cases, the traction on the retina may create a tear.
      - Retinal tears frequently lead to detachments as fluids seep underneath the retina, causing it to separate and detach.

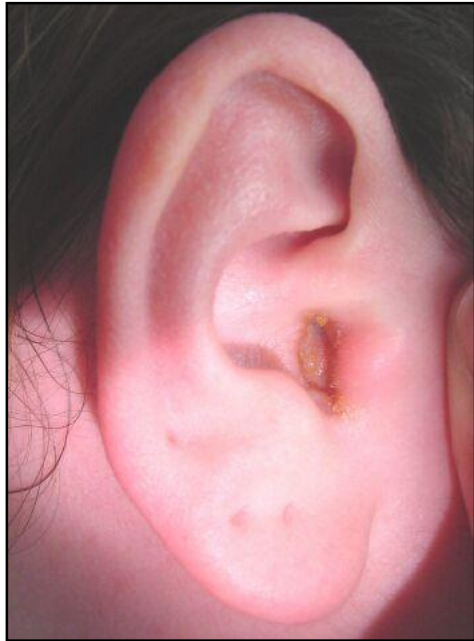- Retinal Detachment
  - Occurs when the retina's sensory and pigment layers separate
  - Because it can cause devastating damage to the vision if left untreated, retinal detachment is considered an **ocular emergency** that requires immediate medical attention and surgery
  - Occurs most frequently in the middle-aged and elderly

- Three types
  - A break in the sensory layer of the retina, and fluid seeps underneath, causing the layers of the retina to separate (most common)
    - nearsighted, eye surgery, or serious eye injury are at greater risk (Nearsighted people are more susceptible because their eyes are longer than average from front to back, causing the retina to be thinner and more fragile)
  - Strands of vitreous or scar tissue create traction on the retina, pulling it loose
    - Diabetes
  - When fluid collects underneath the layers of the retina, causing it to separate from the back wall of the eye
    - Usually occurs in conjunction with another disease affecting the eye that causes swelling or bleeding.

- Signs and Symptoms
  - Light flashes
  - “Wavy,” or “watery” vision
  - Veil or curtain obstructing vision
  - Shower of floaters that resemble spots, bugs, or spider webs
  - Sudden decrease of vision

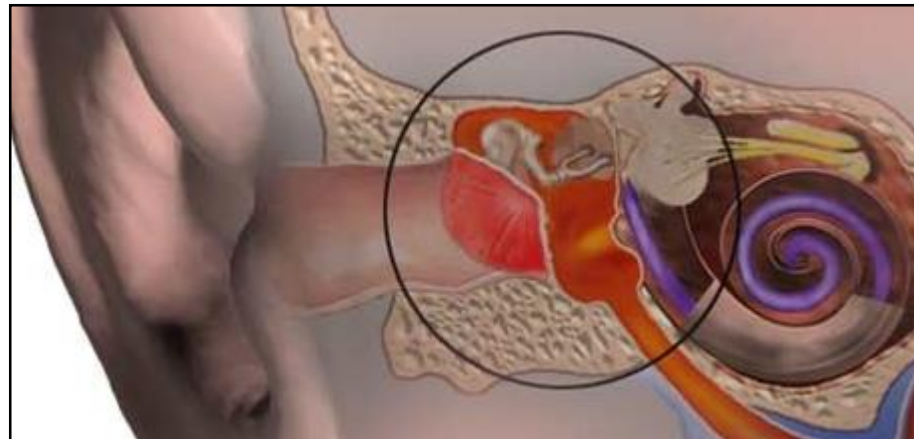- Treatment
  - Depends on the type, severity and location
  - Pneumatic retinopexy
    - Eye is numbed and the surgeon injects a small gas bubble into the vitreous cavity
    - The bubble presses against the retina, flattening it against the back wall of the eye
  - Scleral buckle
    - A tiny sponge or band made of silicone is attached to the outside of the eye, pressing inward and holding the retina in position
    - Is not visible and remains permanently attached to the eye. (may elongate the eye, causing nearsightedness)
  - Silicone oil may be used to reattach the retina.
    - Vitreous gel is replaced with silicone oil
    - After the retina has resealed itself against the back of the eye, a second procedure may be performed to remove the oil

- Soft tissue externally - organs of hearing internally
- Rugby ear
- Direct pressure if external
- Light pressure with side positioning to facilitate drainage



- Inflammation of the auditory canal
- Bacterial (staph) most common
  - Maybe Fungal (aspergillus)
- Caused by traumatic loss of integrity of skin of canal (scratching)
- Characterized by redness, swelling, scaly in appearance, and possible canal obstruction

- Inflammation behind the tympanic membrane
  - Commonly caused by bacteria and viruses resulting in pus, redness, and swelling
- Mild temporary hearing loss is common
- More common in children and following a URI
- 80 % will clear up without intervention



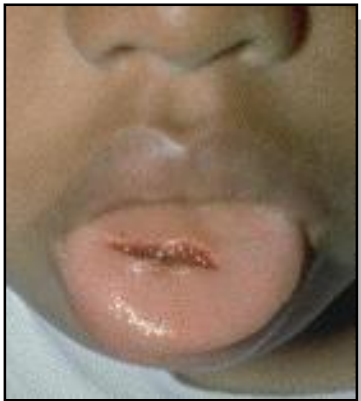

- Inflammation behind the inner ear
  - Commonly caused by bacteria and virus
  - Maybe a sign of meningitis or skull fracture
- Causes vertigo and N/V

- Soft tissue of cheek
- Teeth
- Tongue
- Impaled object
- Fracture of jaw

- 4 x 4's external and internal with pressure applied by patient with thumb and fingers
- Positioning on side to facilitate drainage of blood and saliva

- Blunt trauma primarily
- Fractures of teeth
- Traumatic extraction of tooth
  - If whole tooth can be found, transport in milk
- Bleeding controlled with 4 x 4's by patient through biting



- Lacerations/partial amputation/amputation
- Sudden compression of tongue between teeth
- Gross bleeding
  - May be unmanageable in Prehospital setting
- Patient can attempt to control with 4 x 4 's
- ++++++ painful
  - Amputated portion transported wrapped on ice
- Position patient side lying or prone to prevent aspiration

- Only removed if interfering with ventilation / oxygenation
- Depth of object a concern - posterior pharynx and C-spine proximity

- MOI - presence of spine injury
- Proximity of facial nerves/vessels to bony structures
  - prevent unnecessary movement
- Nasal/oral bleeding and airway compromise #1 concerns
- Wire cutters used to remove wiring in cases of new trauma and old jaw injury