

RESPIRATORY ASSESSMENT

Primary Care Paramedicine

Module: 11
Section: 04



- Respiratory Complaints account for over 15% of all emergency calls in NS (Breathing problems and respiratory arrest)
- Remember respiratory complaints may be associated with exposure to a variety of toxic environments
 - Scene assessment is a key factor

- Scene assessment
 - Safety
 - BSI
 - Identify rescue environments having decreased oxygen levels
 - Gases and other chemical or biological agents
 - Clues to patient information

General Impression of the Patient

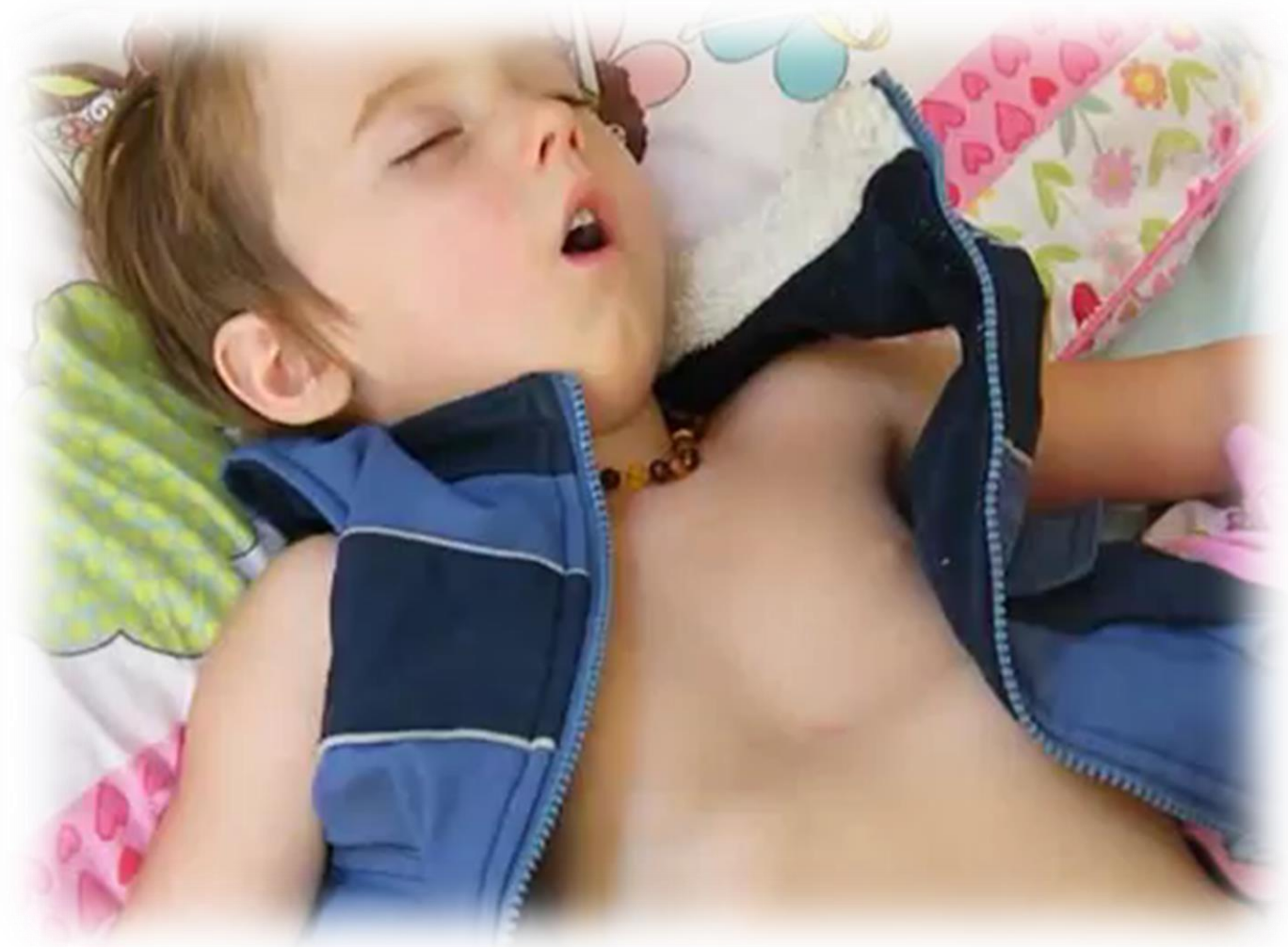- Position
- Color
- Mental status
- Ability to speak
- Respiratory effort



- Major focus is the recognition of life-threatening conditions (ABC's)
- Signs of life-threatening respiratory distress in adults include:
 - ALOC
 - Severe cyanosis
 - Absent breath sounds
 - Audible stridor
 - One or two word dyspnea
 - Tachycardia
 - Pallor or diaphoresis
 - AMU (including retractions)
- What are some other signs of respiratory distress?

Signs of Respiratory Distress

- Nasal flaring
- Intercostal retraction
- Use of accessory muscles
- Cyanosis
- Pursed lips
- Tracheal tugging



- Noisy breathing means partial airway obstruction
- Obstructed breathing is not always noisy
- Brain can only survive minutes in asphyxia
- Ventilation is useless if the airway is blocked
- A patent airway is useless if the patient is apneic
- Act on airway obstruction

- Signs of life-threatening problems
 - Alterations in mental status
 - Severe central cyanosis, pallor, or diaphoresis
 - Absent or abnormal breath sounds
 - Speaking limited to 1–2 words
 - Tachycardia
 - Use of accessory muscles or presence of retractions

- SAMPLE History
- OPQRST History
 - Paroxysmal nocturnal dyspnea and orthopnea
 - Coughing and hemoptysis
 - Associated chest pain
 - Smoking history or exposure to secondary smoke
 - Medication history (compliance, rescue meds?)
- Similar Past Episodes


- If a new condition, or undiagnosed you should decide if the problem is primarily related to
 - Ventilation
 - Diffusion
 - Perfusion

- Pulse rate
 - Tachycardia
 - Sign of hypoxemia, sympathomimetic
 - Bradycardia
 - Severe hypoxemia and imminent arrest
 - First sign of hypoxia in neonates
- BP
 - Hypertension may be a result of the sympathomimetic medications
 - Pulsus paradoxus?

- RR
 - Not always accurate indicator of respiratory status
 - Trends are important
 - Assume as elevated rate is caused by hypoxia
 - Assume a slow rate is impending respiratory arrest
 - Slowing rate with unimproved condition suggests exhaustion
 - Abnormal respiratory patterns may be present
 - Audible noises

Inspection

- Cyanosis
- Pursed lip breathing
- AMU
- Tracheal tug
- JVD
- Cough (productive?)
- SQ Emphysema
- Swelling

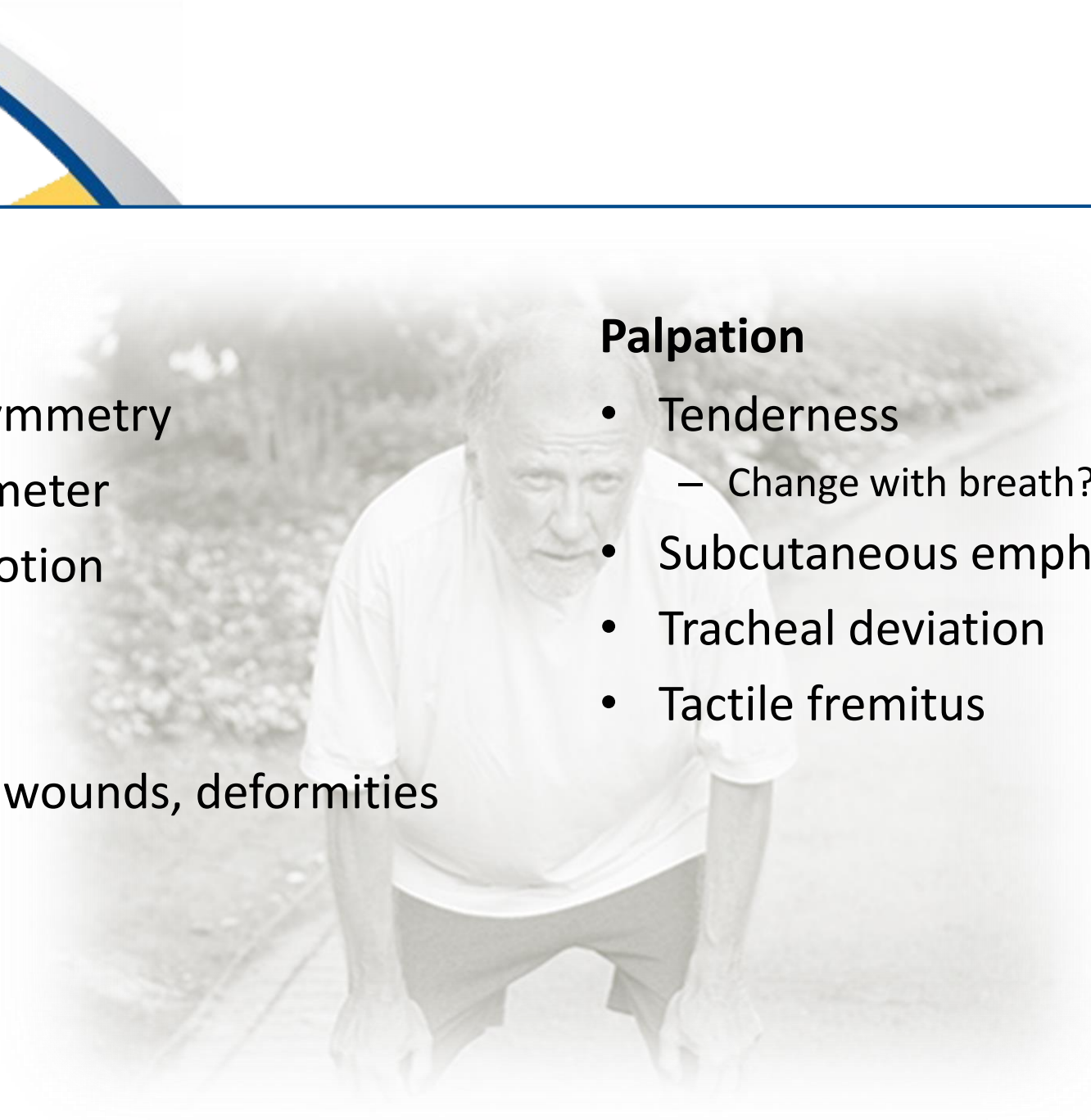

Inspection

- Symmetry/asymmetry
- Increased diameter
- Paradoxical motion
- AMU
- Pain?
- Scars, lesions, wounds, deformities

Palpation

- Tenderness
 - Change with breath?
- Subcutaneous emphysema
- Tracheal deviation
- Tactile fremitus

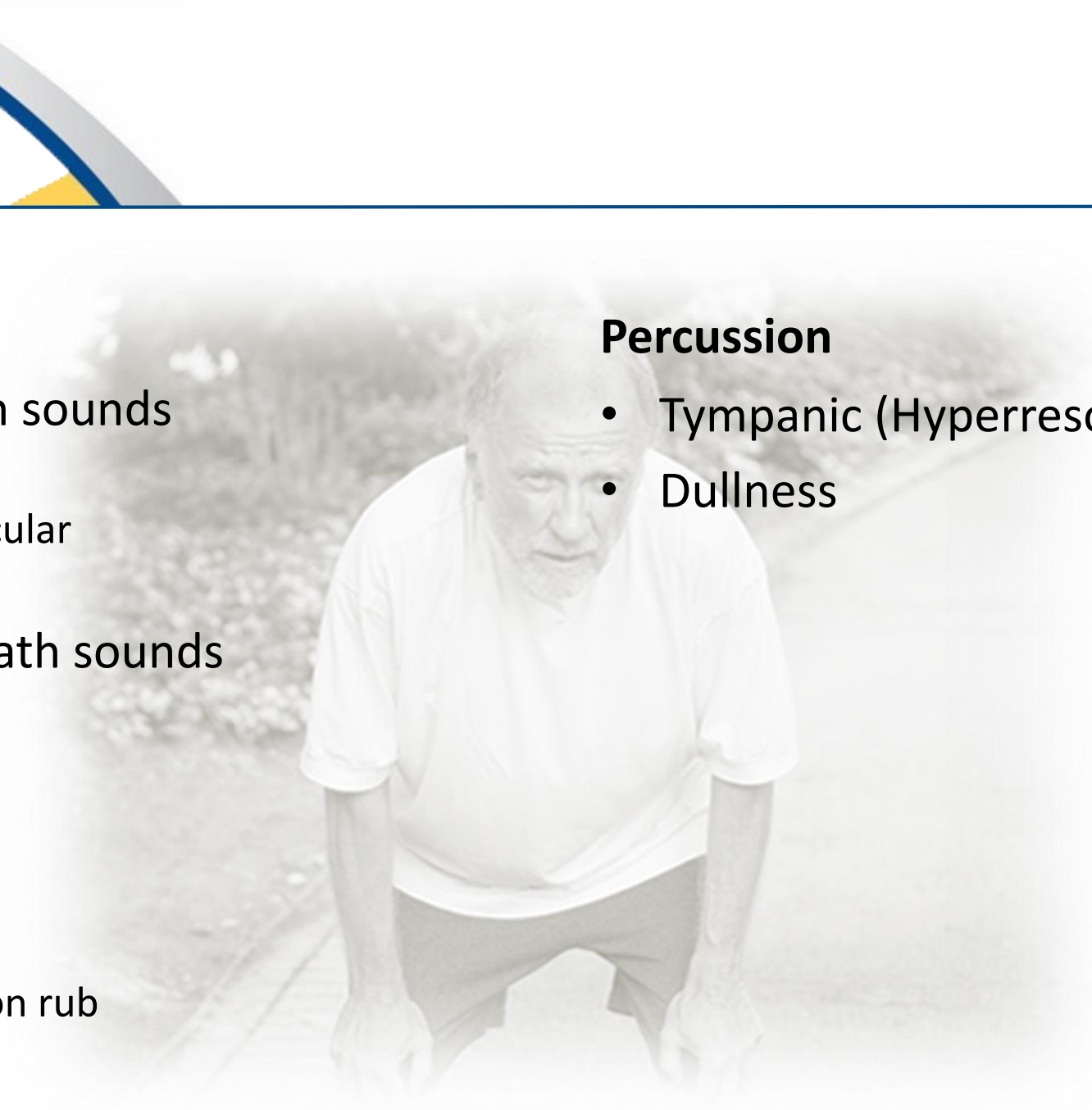


Auscultation

- Normal breath sounds
 - Bronchial
 - Bronchovesicular
 - Vesicular
- Abnormal breath sounds
 - Snoring
 - Stridor
 - Wheezing
 - Rhonchi
 - Crackles
 - Pleural friction rub

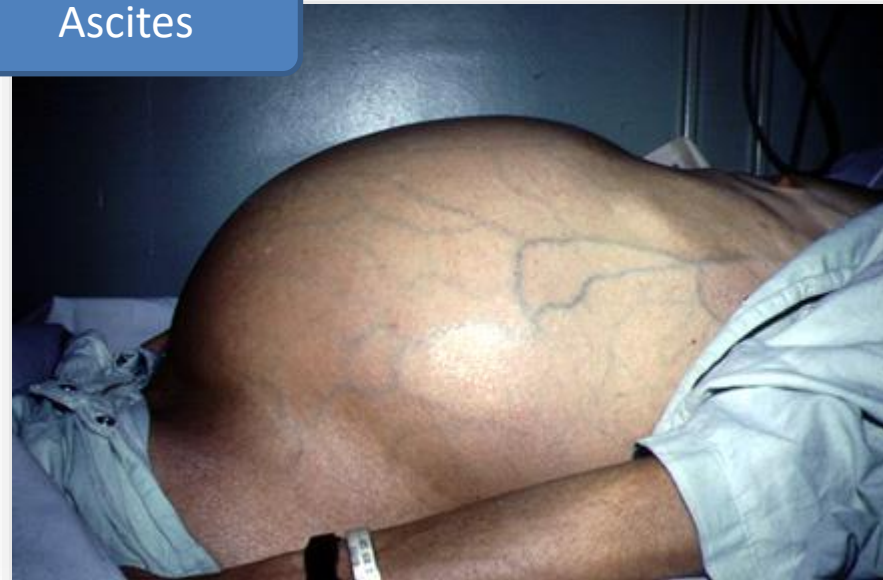Percussion

- Tympanic (Hyperresonant)
- Dullness

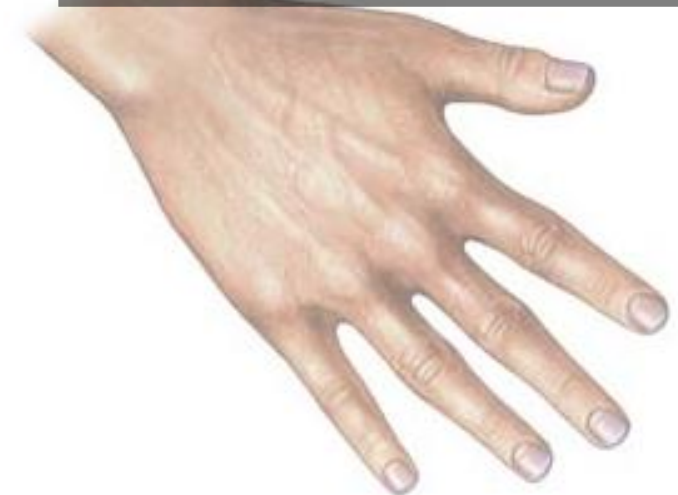
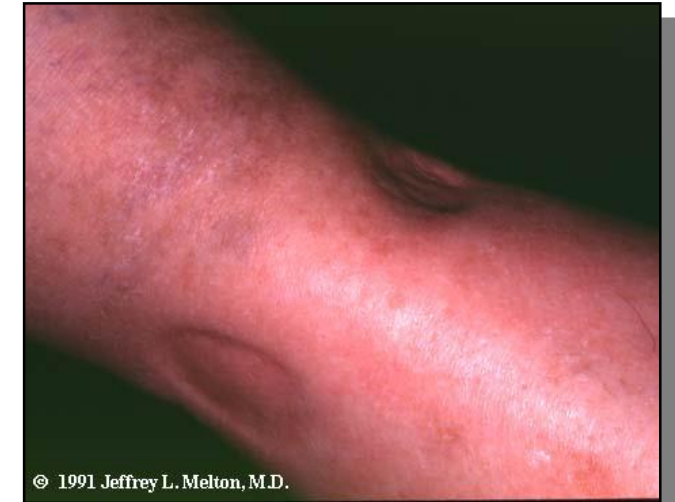
- Abdomen
 - Belly breathing?
 - Pain?
 - Distention

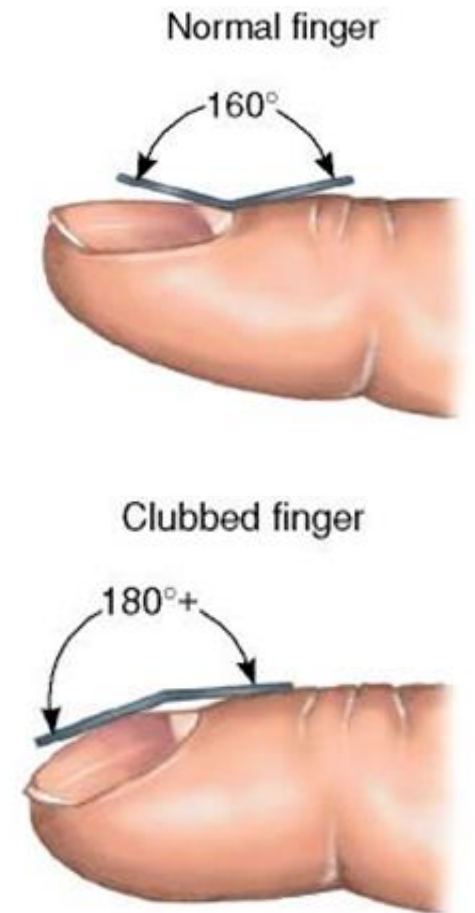
Ascites



- Extremities
 - Peripheral cyanosis
 - Clubbing (from chronic hypoxemia)
 - Carpopedal spasm (from hypercarbia)
 - Edema (pitting?)
 - Skin turgor (tenting?)



- Peripheral cyanosis
- Swelling and redness, indicative of a venous clot
- Finger clubbing, which indicates chronic hypoxia
- Carpopedal spasm (from hypercarbia)
- Edema (pitting?)
- Skin turgor (tenting?)



- Pulse oximetry
- Monitor
- BP
- Glucose
- If intubated
 - Capnography
- Record trends